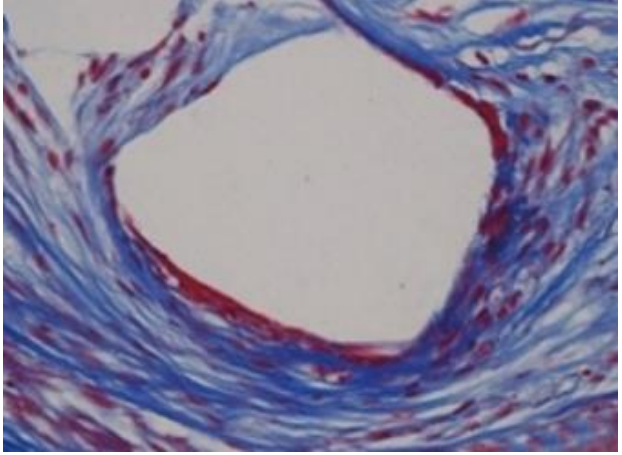
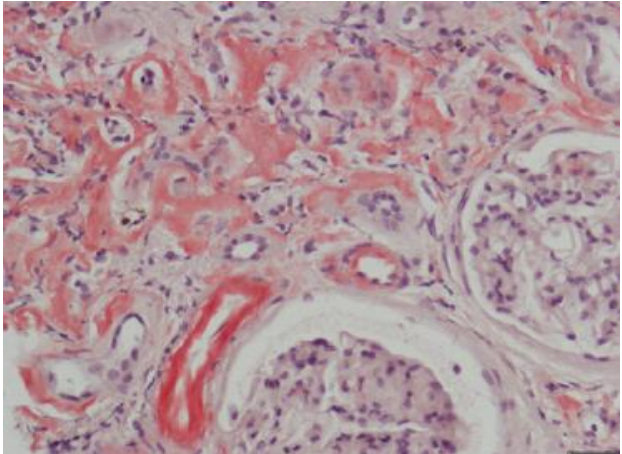
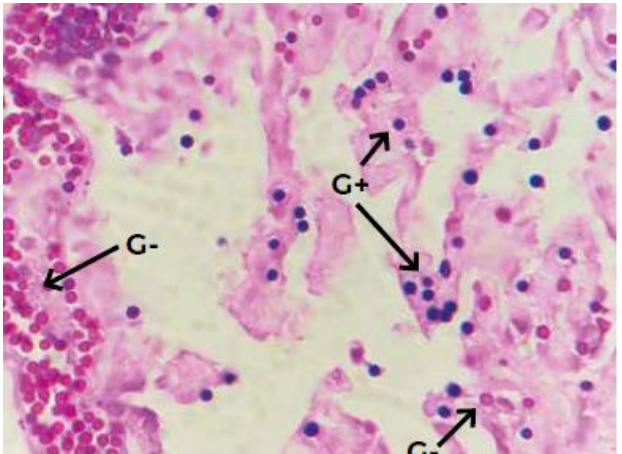
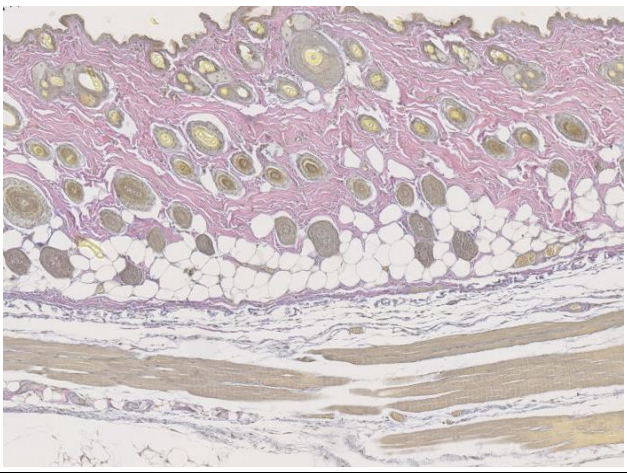
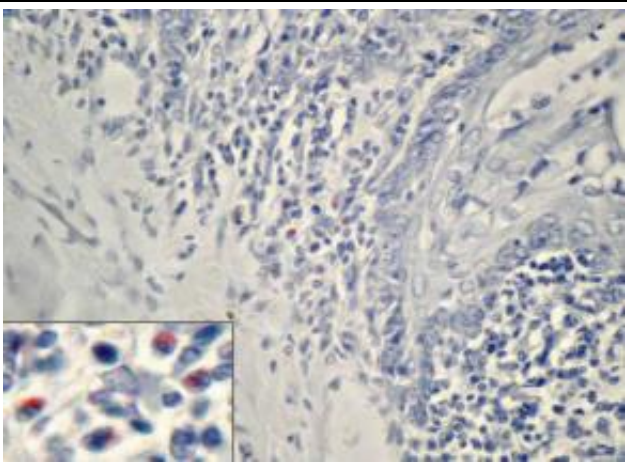
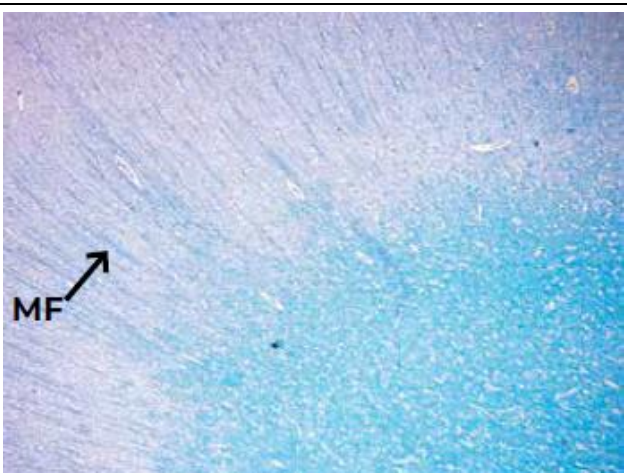


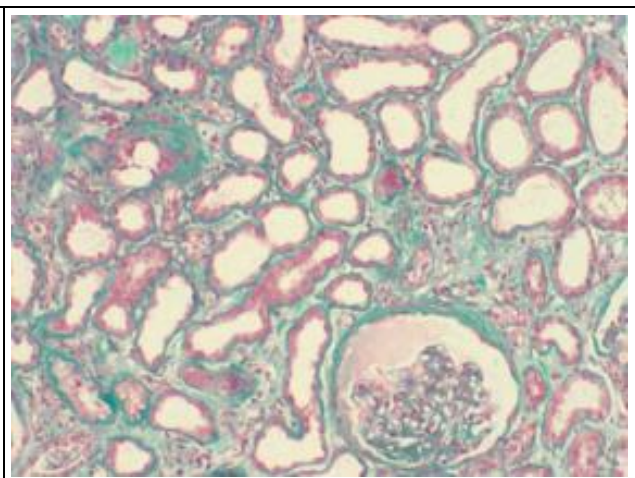
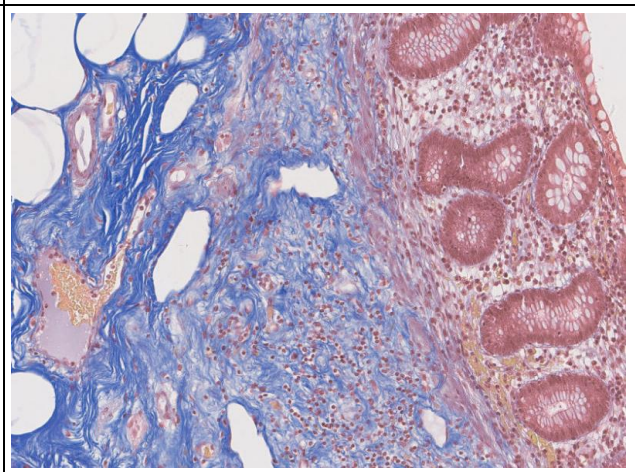
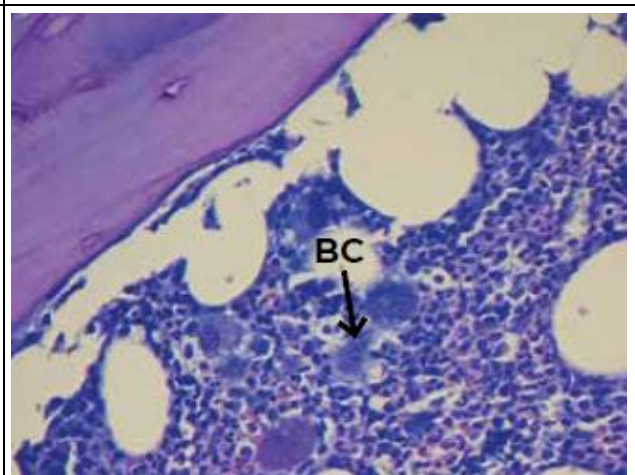
Special Stainings List

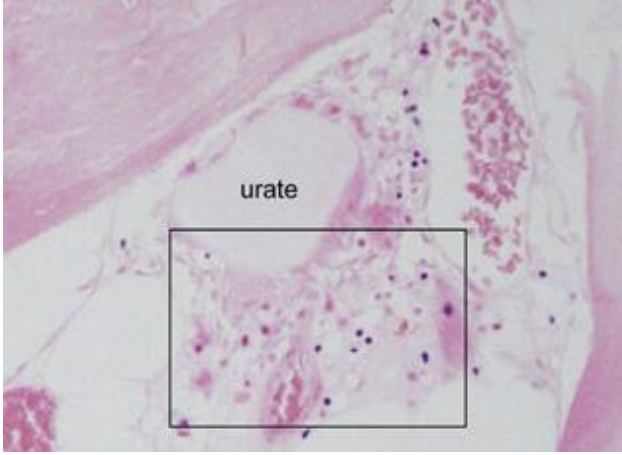
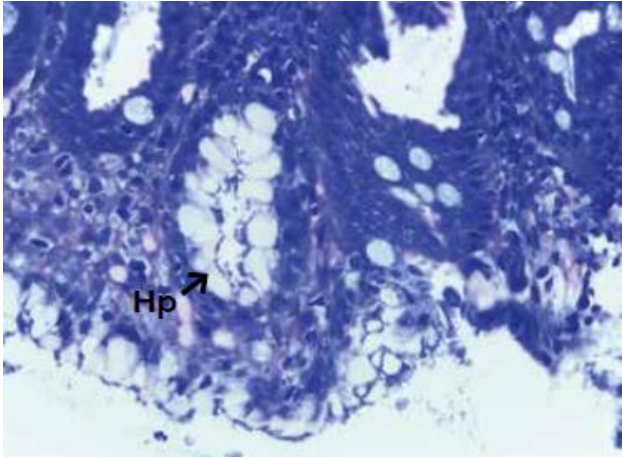
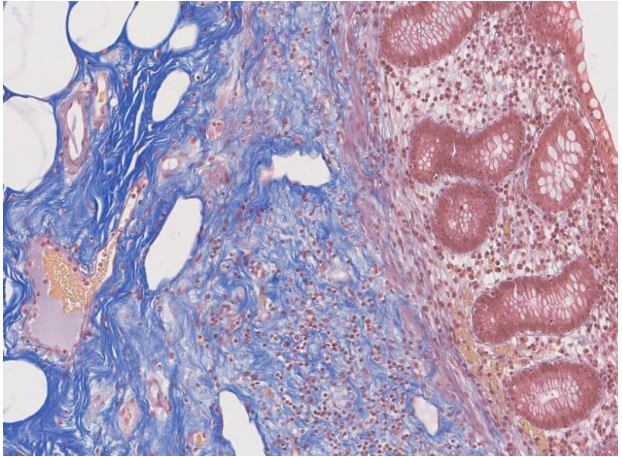
Protocol	Tissue stained	Photo
AFOG	Collagen fibers and reticular connective tissue – dark blue Acid mucosubstances – blue Erythrocytes – red-orange Muscle tissue – bright orange Protein deposits – red Scarred tissue – blue Regenerated tissue - red	
Alcian Blue ¹	Acid mucins – blue - pH 2.5 – most acid mucins (except some of the strongly sulphated groups) - pH 1 – only weakly and strongly sulphated acid mucins - pH 0.2 – only strongly sulphated acid mucins Nuclei – red Erythrocytes – yellow	
Alizarin red ²	Calcium deposits (except oxalate) – orange-red (birefringent)	

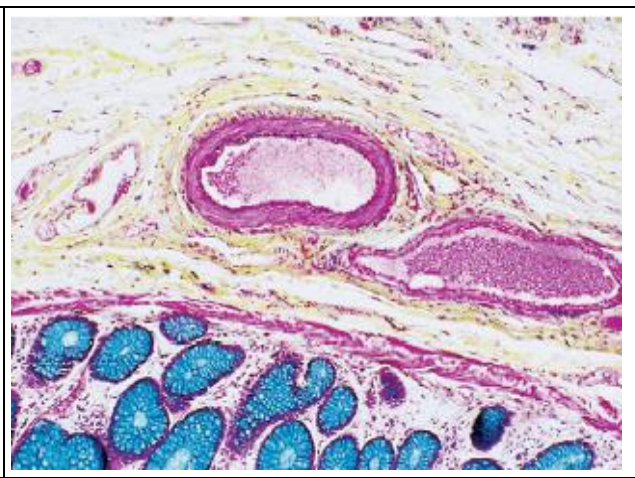
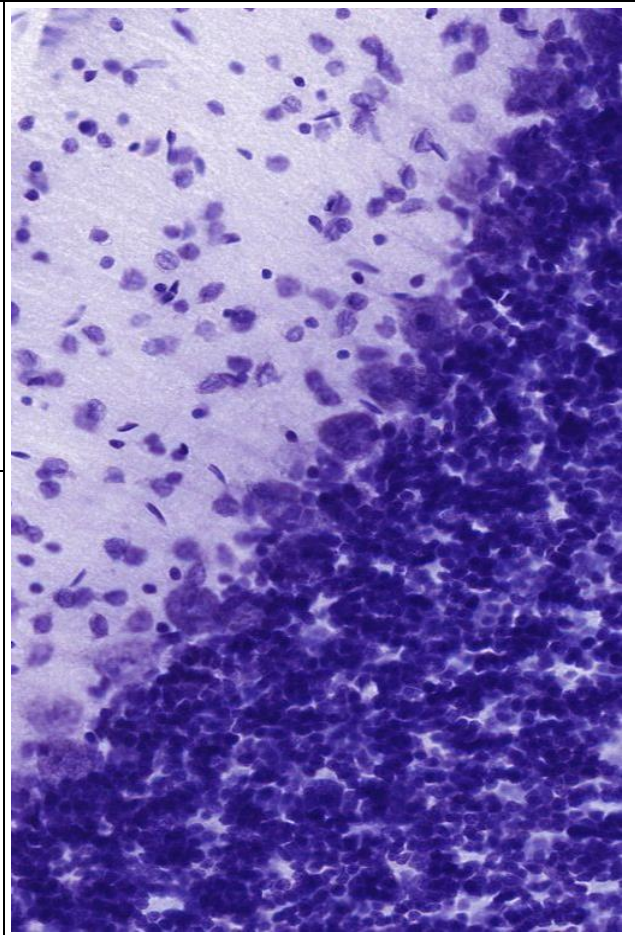
<p>Carstair ³</p>	<p>Fibrin – red Platelets – gray, blue or navy Collagen – bright blue Muscle – red Erythrocytes – Clear yellow</p>	
<p>Congo Red ⁴</p>	<p>Amyloid, elastic fibers, eosinophil granules – red (green in polarized microscope) Nuclei – blue</p>	
<p>Gram ¹</p>	<p>Gram + bacteria – blue to purple Gram - bacteria – Red to magenta</p>	

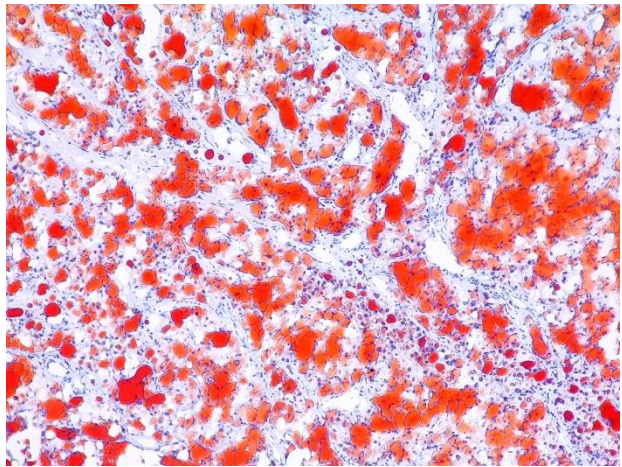
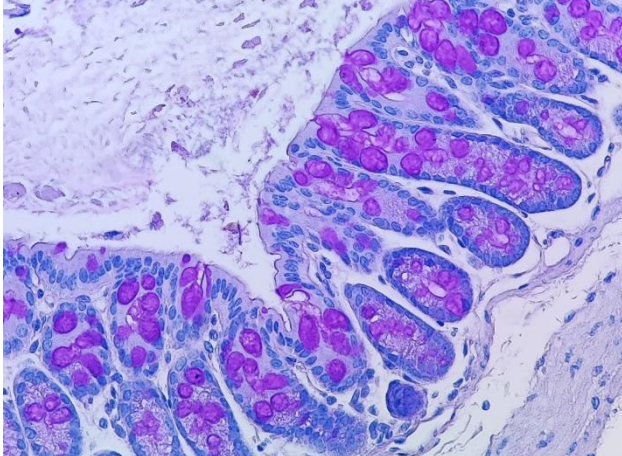
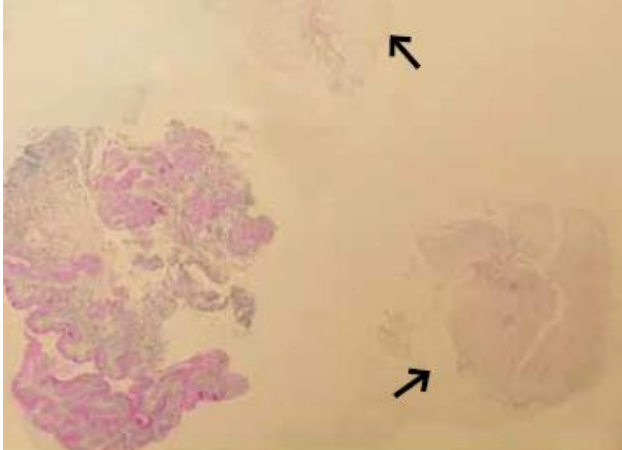
<p>Herovici's Stain</p>	<p>Young collagen and reticulin – blue Mature collagen – red Cytoplasm – yellow Nuclei – black</p>	
<p>Luna⁵</p>	<p>Erythrocytes – bright red Eosinophilic granules – red Charcot-Leyden crystals – red Background – blue</p>	
<p>Luxol Fast Blue + Cresyl Violet¹</p>	<p>Myelin – blue Erythrocytes – purple Nissl body – purple</p>	

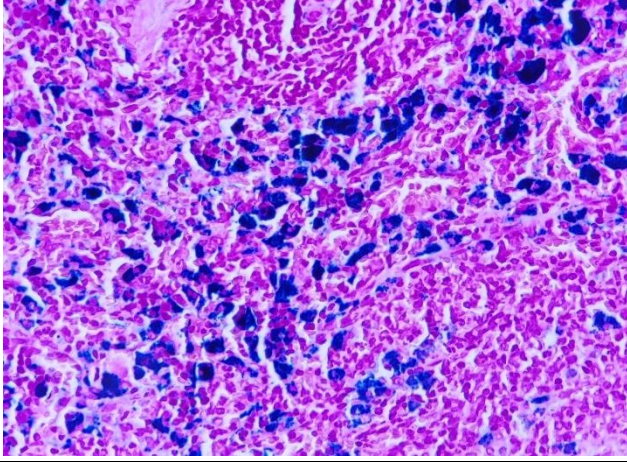
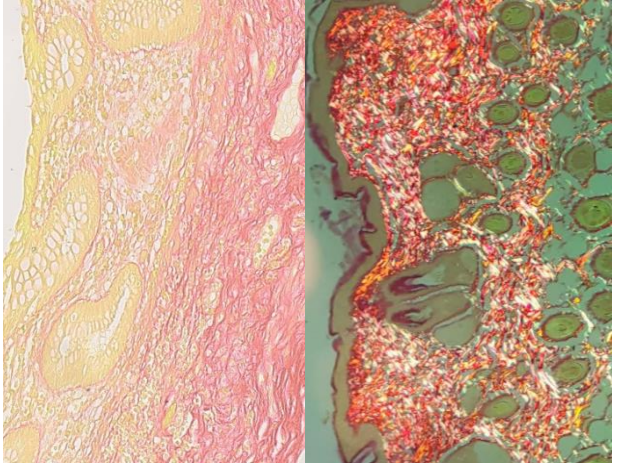

<p>Luxol Fast Blue + Eosin</p>	<p>Myelin – blue Erythrocytes – purple Other structures – pink</p>	
<p>Luxol Fast Blue no Counterstain⁶</p>	<p>Myelin – blue Erythrocytes – purple Nissl body – purple</p>	
<p>Masson's Trichrome</p>	<p>Nuclei – black Muscle fibers, keratin and cytoplasm – bright red Collagen and mucus – blue Erythrocytes – yellow to orange</p>	

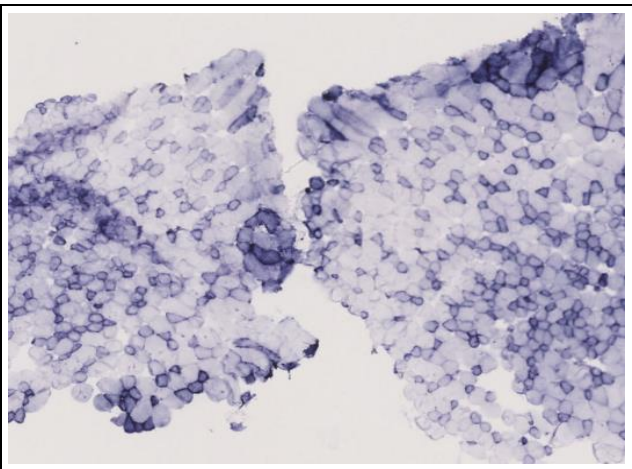
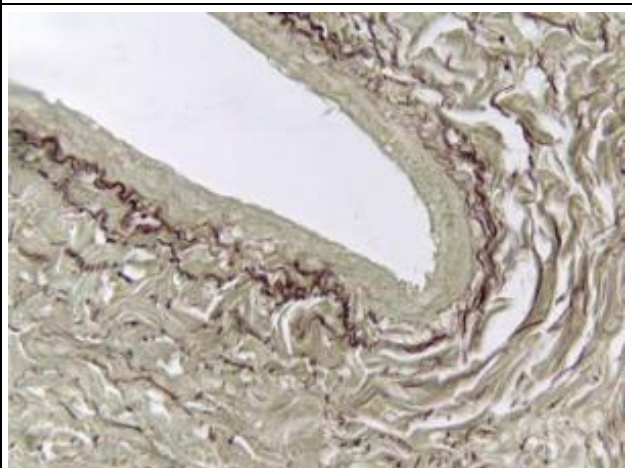
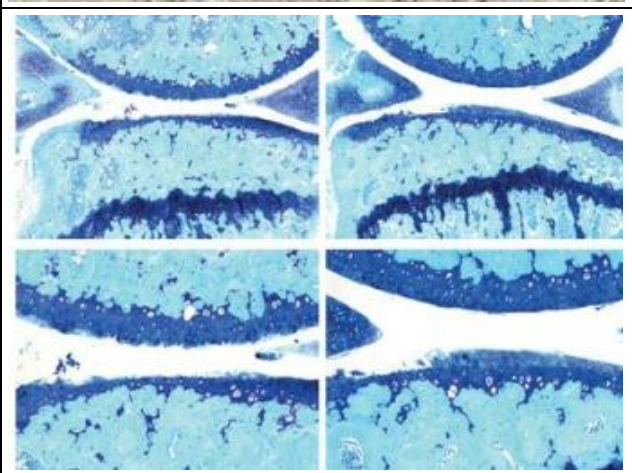
<p>Masson's Trichrome + Light Green ⁷</p>	<p> Nuclei – dark blue Collagen fibers – Turquoise green Mucins – green Cytoplasm – red Muscle fibers - red </p>	
<p>Masson's Trichrome for frozen muscle</p>	<p> Nuclei – blue to black Intercellular fiber – red Collagen – blue Cytoplasm – red Mucin – blue Keratin – red Argentaffin granules – black or red Neuroglia fibers - red </p>	
<p>May-Grünwald Giemsa ¹</p>	<p> Basophilic cytoplasm – Variants of blue Acidophilic cytoplasm – Purple Nuclei – blue Parasites – blue </p>	

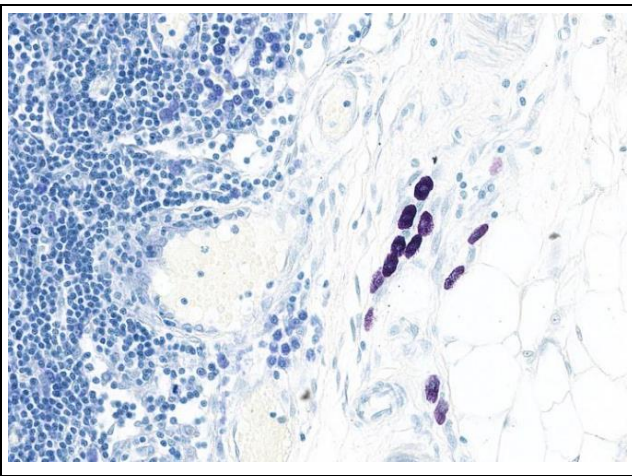
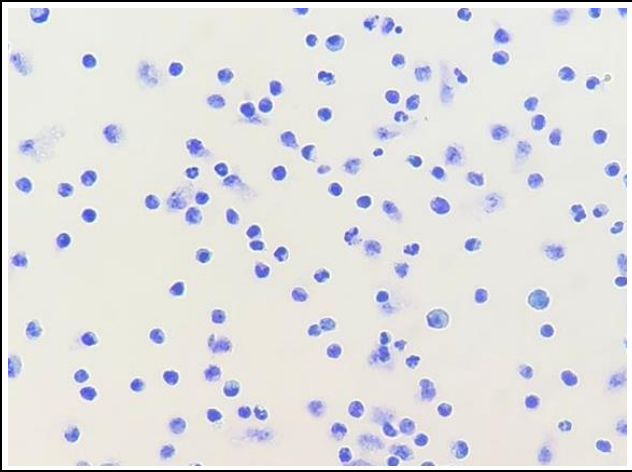
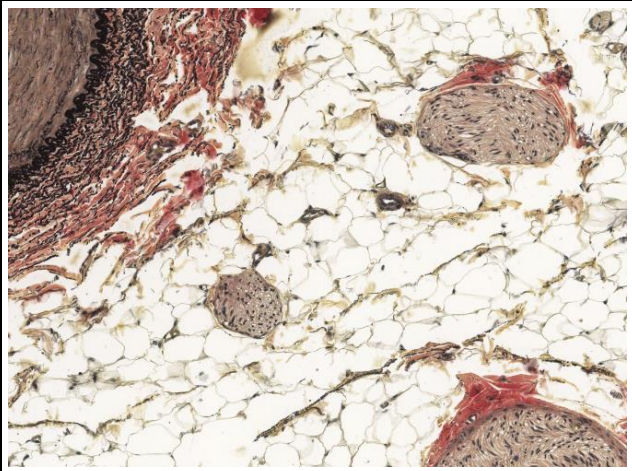
<p>Modified Giemsa bone marrow ⁸</p>	<p>Nuclei – dark blue Cytoplasm – pink to light blue Bone trabeculae – pink Blood cells – red and blue</p>	
<p>Modified Giemsa microorganisms ¹</p>	<p>Nuclei – dark blue Microorganisms (helicobacter pylori, Giardia, others) – dark blue Erythrocytes – green</p>	
<p>Modified Masson's Trichrome for cardiac tissue</p>	<p>Nuclei – blue to black Intercellular fiber – red Collagen – blue Cytoplasm – red Mucin – blue Keratin – red Argentaffin granules – black or red Neuroglia fibers – red</p>	

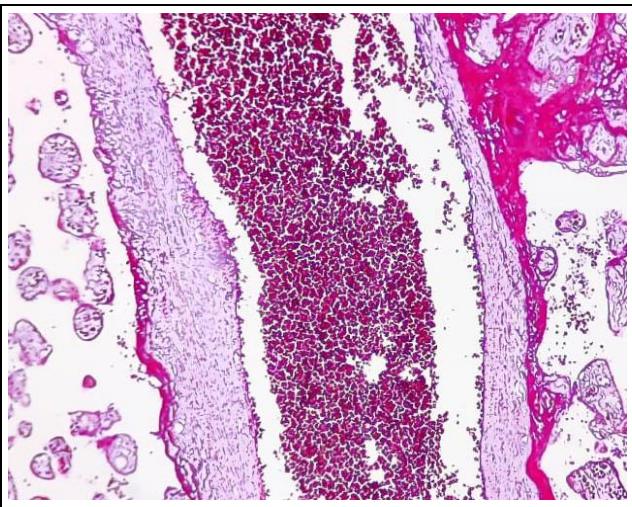
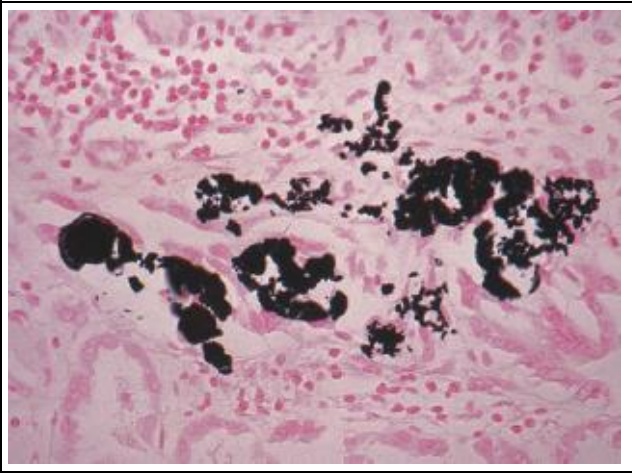
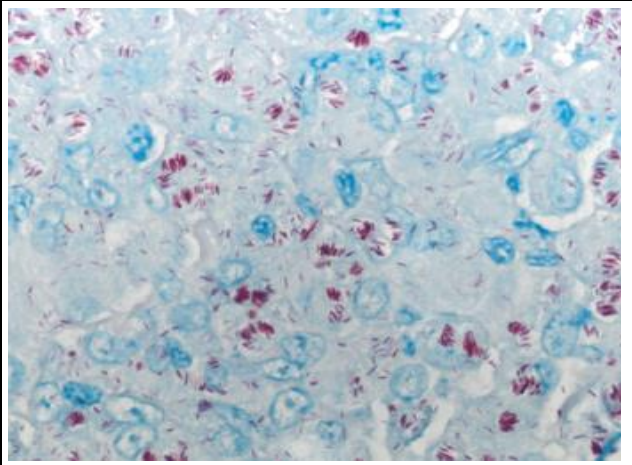
<p>Modified Russell-Movat Pentachrome 4</p>	<p>Nuclei – black Elastic fibers – black Collagen – yellow Ground substances and mucins – blue to green Muscle – red Fibrinoid – intense red</p>	
<p>Nissl for paraffin 9</p>	<p>Nissl body – purple-pink Basic neuronal structure – purple</p>	
<p>Nissl for cryo 9</p>	<p>Nissl body – purple Basic neuronal structure – purple</p>	


<p>Oil Red</p>	<p>Lipids – red Nuclei – blue</p>	
<p>PAS</p>	<p>Nuclei – Blue to black Neutral/sialomucins – magenta Various glycoproteins, early lipofuchsins – magenta Glycogen – magenta</p>	
<p>PAS-Diastase¹</p>	<p>Nuclei – Blue to black Neutral/sialomucins – magenta Various glycoproteins, early lipofuchsins - magenta</p>	

<p>PERLS</p>	<p>Ferric iron – blue Nuclei – magenta Background – pink</p>	
<p>Picro-Sirius Red</p>	<p>Collagen – red (polarized – bright yellow or orange) Background – pale yellow Reticular fibers and the basal laminae of cerebral capillaries – red (polarized – green) Muscle fibers – yellow Keratin - yellow</p>	
<p>Safranin ¹⁰</p>	<p>Cartilage – orange to red Mucin – orange to red Mast cell granules – orange to red Nuclei – black Background – bluish green</p>	

<p>SDH</p>	<p>Darker blue – more mitochondrial activity</p>	
<p>Taenzer-Unna¹¹</p>	<p>Elastic fibers – purplish brown Other tissue – light green</p>	
<p>Toluidine Blue + Fast Green¹²</p>	<p>Nuclei – blue Mast cells, cartilage, epithelial mucins – pink to red and violet Background - green</p>	

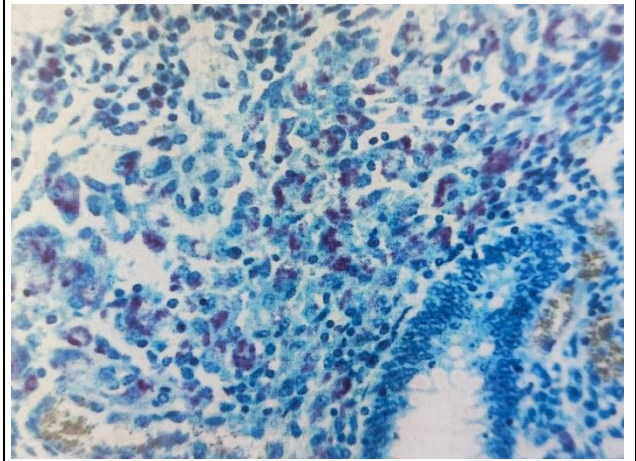
<p>Toluidine Blue ⁹</p>	<p>Nuclei – blue Overall structure – blue Mast cells, cartilage, epithelial mucins – pink to red and violet</p>	
<p>Toluidine Blue for smears</p>	<p>Nuclei – blue Mast cells – pink to red and violet</p>	
<p>Verhoeff ⁹</p>	<p>Elastic fiber – black Collagen – red magenta Background – yellow to orange</p>	

<p>Von Biscaia</p>	<p>Erythrocytes – red Background – pink</p>	
<p>Von Kossa + Trichrome⁴</p>	<p>Calcium and mineralized bone – black Osteoid – red Other structures – yellow</p>	
<p>Ziehl-Neelsen⁴</p>	<p>Acid-alcohol resistant bacteria – red Background – blue</p>	



Ziehl-Neelsen Fite ¹³

Acid resistant bacteria – red
Background - blue





References for the photographs

- 1 – Diapath. *Special Stains Handbook*. 2023, 1st edition
- 2 – Yin, Xiao-xue & Chen, Zhong-qiang & Liu, Zhong-jun & Ma, Qing-Jun & Dang, Geng-ting. (2007). Icariine stimulates proliferation and differentiation of human osteoblasts by increasing production of bone morphogenetic protein 2. *Chinese medical journal*. 120. 204-10. 10.1097/00029330-200702010-00006.
- 3 – Lim, Kyung Seob & Hong, Young & Hachinohe, Daisuke & Ahmed, Khurshid & Jeong, Myung & Kim, Jeong-Hoon & Sim, Doo & Lee, Min Goo & Park, Keun-Ho & Kim, Jung-Tae & Ahn, Youngkeun & Cho, Jeong & Park, Jong & Song, S. & Jung, Kyoung & Cho, Dong & Kang, Jung. (2011). Effect of a Dual Drug-Coated Stent With Abciximab and Alpha-Lipoic Acid in a Porcine Coronary Restenosis Model. *Korean circulation journal*. 41. 241-7. 10.4070/kcj.2011.41.5.241.
- 4 – Bancroft, J.D., Gamble, M.. *Theory and Practice of Histological Techniques*. (2002), Elsevier, 5th edition.
- 5 – VH Tomasi, MÁ Pérez & ME Itoiz (2008) Modification of Luna's technique for staining eosinophils in the hamster cheek pouch, *Biotechnic & Histochemistry*, 83:3-4, 147-151, DOI: 10.1080/10520290802352424
- 6 – Gnanapavan, S., Jaunmuktane, Z., Baruteau, K.P. *et al.* A rare presentation of atypical demyelination: tumefactive multiple sclerosis causing Gerstmann's syndrome. *BMC Neurol* **14**, 68 (2014). <https://doi.org/10.1186/1471-2377-14-68>
- 7 – Sousa, Helena & Verdelho, Miguel & Mendes, Marco & Carvalho, Fernanda & Nolasco, Fernando. (2014). Renal dysfunction in a patient with a Roux-en-Y gastric bypass surgery. *Portuguese Journal of Nephrology and Hypertension*. *Port J Nephrol Hypert* 2014; 28(4): 000-000.
- 8 - Allaey, Isabelle & Rusu, Daniel & Picard, Sylvain & Pouliot, Marc & Borgeat, Pierre & Poubelle, Patrice. (2011). Osteoblast retraction induced by adherent neutrophils promotes osteoclast bone resorption: Implication for altered bone remodeling in chronic gout. *Laboratory investigation; a journal of technical methods and pathology*. 91. 905-20. 10.1038/labinvest.2011.46.
- 9 – www.histologyguide.com
- 10 – Lu, Hongbin & Liu, Feifei & Chen, Huabin & Chen, Can & Qu, Jin & Xu, Daqi & Zhang, Tao & Zhou, Jingyong & Hu, Jianzhong. (2016). The Effect of Low-Intensity Pulsed Ultrasound on Bone-Tendon Junction Healing: Initiating after Inflammation Stage. *Journal of Orthopaedic Research*. 34. n/a-n/a. 10.1002/jor.23180.
- 11 – de Brito-Gitirana, L., Valdiero, J., & Cunha, R. (2019). Replacement of the background stain in the Taenzer-Unna acid Orcein method: contemporary perspective on research and histopathological diagnosis. *Acta Scientiae Anatomica*, 1(2), 131-135. Retrieved from <http://actasanatomica.com/journal/index.php/asa/article/view/34>
- 12 - Philippe, Clement & Little, Christopher & Smith, Margaret & Cottreaux, Céline & Merciris, D. & Meurisse, Sandrine & Mollat, Patrick & Touitou, Robert & Brebion, Franck & Gosmini, Romain & De Ceuninck, Frédéric & Botez, Iuliana & Lepescheux, liên & Aar, Ellen & Christophe, Thierry & Vandervoort, Nele & Blanqué, Roland & Comas, Daniel & Deprez, Pierre & Amantini, D.. (2021). Pharmacological characterization of GLPG1972/S201086, a potent and selective small molecule inhibitor of ADAMT5. *Osteoarthritis and Cartilage*. 30. 10.1016/j.joca.2021.08.012.
- 13 – DiaPath. *Acid Fast bacteria acc. Ziehl-Neelsen modified acc. Fite*.